

Long-Term Remission of Adenoid Cystic Tongue Carcinoma with Low Dose Naltrexone and Vitamin D3 – A Case Report

Akbar Khan

Medical Director, Medicor Cancer Centres Inc. 4576 Yonge St., Suite 301 Toronto, ON M2N 6N4, Canada.

Abstract

Naltrexone (ReVia®) is a long-acting oral pure opiate antagonist which is approved for the treatment of alcohol addiction as a 50mg per day tablet. The mechanism of action is complete opiate blockade, which removes the pleasure sensation derived from drinking alcohol (created by endorphins). Low Dose Naltrexone (“LDN”) in the range of 3-4.5 mg per day has been shown to have the opposite effect – brief opiate receptor blockade with resulting upregulation of endogenous opiate production. Through the work of Bihari and Zagon, it has been determined that the level of the endogenous opiate methionine-enkephalin is increased by LDN. Met-enkephalin is involved in regulating cell proliferation and can inhibit cancer cell growth in multiple cell lines. Increased met-enkephalin levels created by LDN thus have the potential to inhibit cancer growth in humans. Phase II human trials of met-enkephalin, case reports published by Berkson and Rubin, and the clinical experience of Bihari confirmed the potential role of LDN in treating pancreatic and other cancers. However, large scale trials are lacking and are unlikely to be funded given the current non-proprietary status of naltrexone. A case report is presented of successful treatment of adenoid cystic carcinoma as further evidence of LDN’s potential as a unique non-toxic cancer therapy.

Key Words: Naltrexone, Cancer, Adenoid cystic, Vitamin D

Introduction

Naltrexone (ReVia®) is a long-acting oral pure opiate antagonist which is approved for the treatment of alcohol addiction in 50mg per day dosing [1]. The mechanism of action is complete opiate blockade, which removes the pleasure sensation derived from drinking alcohol (created by endorphins). Dr. Bernard Bihari, a neurologist who practiced in New York, discovered that naltrexone when used in much smaller doses (in the range of 3-4.5 mg per day) can have anti-cancer effects. Through his clinical work, he determined that Low Dose Naltrexone (“LDN”) could be used as a treatment for many cancer types, even for advanced cases (unpublished, reported at www.ldninfo.org). The proposed mechanism was a brief opiate blockade which triggered a surge in endogenous opiate production (endorphins and enkephalins) through a feedback mechanism. This includes an increased level of a specific endogenous opiate called methionine-enkephalin (“met-enkephalin”).

Dr. Ian Zagon conducted extensive *in vitro* work showing that the endogenous opiate met-enkephalin (also known as Opioid Growth Factor or “OGF”) is involved in regulating cell proliferation and can inhibit cancer cell growth in multiple cell lines [2-6]. Successful Phase I and II human trials were conducted with met-enkephalin in pancreatic cancer, confirming the *in vitro* findings [7-9]. It was also discovered that met-enkephalin can increase natural killer cell activity, which can also target cancerous cells [10].

Dr. Burt Berkson and Dr. Daniel Rubin subsequently published case reports supporting the role of low dose naltrexone in treatment of pancreatic cancer and lymphoma [11-13]. Here, a case is presented of successful therapy of a rare adenoid cystic carcinoma using low dose naltrexone, whose effects against this cancer type have not previously been documented.

Case Presentation

A 58 year old male (Mr. Michel Charest from Montréal, Québec) presented to his family doctor with new swallowing problems, hemoptysis and nausea. There was a history of smoking 1/2 pack of cigarettes per day for about 15 years, alcohol intake of 2 standard drinks per day, high cholesterol and a remote history of jaundice. The only medication taken was atorvastatin. The patient was referred to an otolaryngologist, who noted a mass at the left tongue base and made the diagnosis through biopsy.

He was assessed by the head and neck team at a regional cancer hospital. Contrast-enhanced Computed Tomography (“CT”) scan was done showing a 3.2 cm mass at the left tongue base extending across the midline, and an absence of adenopathy. No metastases or enlarged lymph nodes were observed in the chest. Contrast-enhanced Magnetic Resonance Imaging (“MRI”) was then performed, confirming the 3.0 cm T2 hyper intense enhancing mass which infiltrated the extrinsic muscles of the anterior tongue, but did not invade the larynx or hyoid bone (*Figure 1*). The tumour stage was thus determined to be T₄N₀M₀. Blood tests performed soon after diagnosis revealed minor abnormalities (*Table 1*).

The primary treatment proposed was surgical - complete glossectomy, along with laryngectomy were strongly recommended. However, if the patient refused surgery, tomotherapy would be considered. Due to the drastic loss of quality of life with the proposed surgery, the patient declined therapy and began seeking other opinions. He consulted a surgeon in France who advised that a less aggressive surgery with free-flap reconstruction could be attempted. Radiation and chemotherapy were not recommended.

Approximately 1 year after initial diagnosis, the patient presented for an opinion regarding non-toxic unconventional therapy. A number of options were proposed which were undergoing clinical trials at the time, or had published evidence

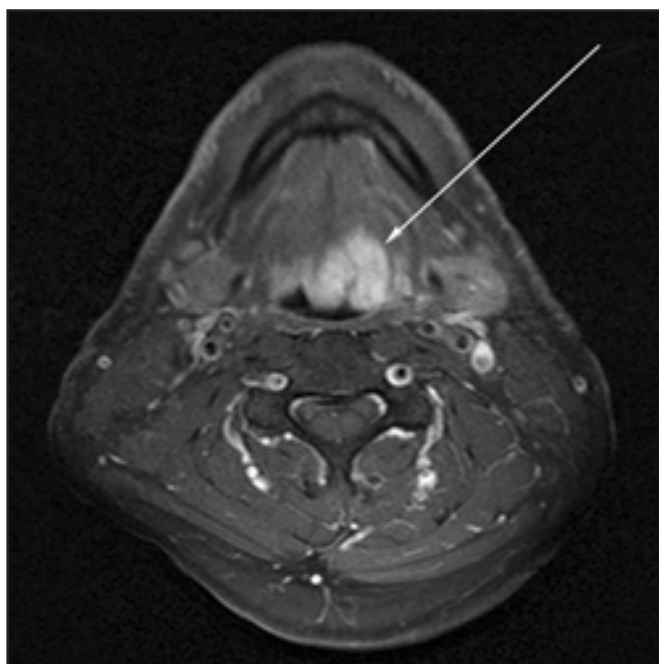


Figure 1. Axial T1 post gadolinium MRI image demonstrating large enhancing adenoid cystic carcinoma of left tongue base, extending across the midline (pre-treatment).

Table 1. Blood tests 8 months before treatment with LDN.

Test	Result	Normal Range
HB	163	140-175 g/L
WBC	7.3	4.0-11.0x 10 ⁹ /L
PLT	150	150-400x 10 ⁹ /L
Na	145	134-144 mmol/L
K	4.3	3.5-5.5 mmol/L
Cl	107	98-108 mmol/L
GLUC	3.7	3.9-11.0 mmol/L
ALT	19	5-40 U/L
AST	19	15-55 U/L
ALKP	69	40-125 U/L
BILI	9	3-17 µmol/L
ALBU	44	35-51 g/L
UREA	8.9	3.2-8.5 mmol/L
CREAT	95	55-120 µmol/L

supporting their use. These included oral dichloroacetate [14-16] (apoptosis inducer/metabolic therapy), low dose naltrexone, ammonium tetrathiomolybdate [17-20] (copper chelator / angiogenesis inhibitor), and combination therapy with radiation. Risks and benefits were discussed. He was reluctant to have radiotherapy and was interested in medication with low side effects, so LDN was selected. High dose vitamin D was also added (10,000 IU per day of oral liquid vitamin D3) since it can act as a differentiating agent, thus potentially enhancing the cancer therapy [21-24]. The target blood level of 25-hydroxy vitamin D was the upper end of the normal range, as specified by the patient's local blood lab. The patient was also asked to moderate his alcohol consumption.

LDN was started at a dose of 3mg orally once a day at bedtime. This reduced dose was selected to ensure that sleep was not disrupted by insomnia or vivid dreams (known side effects of LDN). Since the LDN was well-tolerated, the dose was increased to 4 mg daily at bedtime. The patient also added oral vitamin C 2000mg daily for the first 3 months of therapy.

The patient felt improvement in symptoms with LDN therapy, and decided to continue under the direction of his family doctor, with periodic re-assessment from his otolaryngologist at the regional cancer hospital. After 3 months of therapy, blood tests were repeated and demonstrated normalization of most values (Table 2). After one year of therapy, the 25-hydroxy vitamin D was 268nmol/L (normal range 75-250 nmol/L). Vitamin D was reduced to 5,000 IU daily. The patient felt well and had no further symptoms from his cancer. Therapy was continued with no dose changes, and after a total of 2 years of LDN and vitamin D, the MRI was repeated. Relevant findings included marked regression of the tumour from a T2 hyperintense/T1 hypointense contrast-enhancing 3.0 cm mass to a non-enhancing area of T1 and T2 hypointensity (Figure 2). The maximal dimension of hypointensity was measured to be 1.6cm. There were no strongly diffusion restricting lesions noted and there was no adenopathy. This was interpreted by the radiologist as a probable absence of active disease.

The patient's doctors elected not to order frequent

Table 2. Blood tests after 3 months of treatment with LDN + vitamin D.

Test	Result	Normal Range
HB	160	140-175 g/L
WBC	6.7	4.0-11.0x 10 ⁹ /L
PLT	130	150-400x 10 ⁹ /L
Na	143	134-144 mmol/L
K	4.6	3.5-5.5 mmol/L
Cl	106	98-108 mmol/L
GLUC	5.1	3.9-11.0 mmol/L
ALT	26	5-40 U/L
AST	28	15-55 U/L
ALKP	65	40-125 U/L
BILI	10	3-17 µmol/L
ALBU	45	35-51 g/L
UREA	7.0	3.2-8.5 mmol/L
CREAT	92	55-120 µmol/L

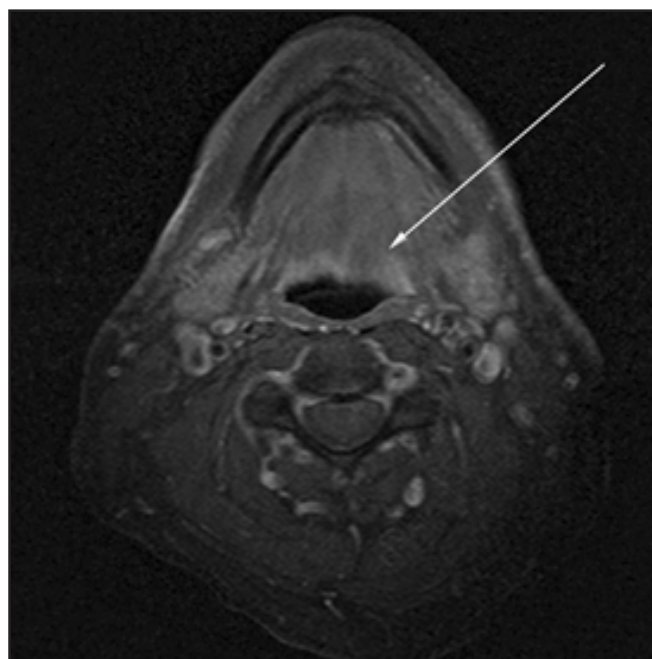


Figure 2. Axial T1 post gadolinium MRI image demonstrating resolution of enhancing mass (2 years post-treatment).

imaging or blood tests since he was clinically normal. At the time of this writing, the patient has been re-assessed by the otolaryngologist who confirmed he remains without clinical evidence of cancer. He has remained asymptomatic on therapy, and is just approaching the four year mark (47 months so far). There were no complications from the LDN or high dose vitamin D, and no conventional therapy was ever introduced.

Discussion

Adenoid cystic carcinoma is a rare neoplasm which generally arises from the salivary glands in the head and neck. The natural history of untreated adenoid cystic carcinoma is a relentless disease progression with eventual metastases and death after a number of years [25]. This case illustrates successful long-term therapy of stage T₄N₀M₀ adenoid cystic carcinoma of the tongue base. The patient declined traditional radical surgery consisting of complete glossectomy and complete laryngectomy, thus escaping the inevitable associated loss of quality of life. The patient has achieved nearly a four year remission of his cancer based on his clinical status and the last MRI scan. With further imaging in future, clarity may be

achieved regarding a possible duration of remission beyond 4 years. The entire therapy was safe, completely non-toxic, and also cost effective (less than \$100 per month).

Since two therapies were administered simultaneously (LDN and high dose vitamin D), the degree of contribution of each towards the cancer regression cannot be ascertained with certainty. However, this case example is consistent with clinical findings of Berkson and Bihari regarding the anti-cancer effects of LDN. It is possible vitamin D acted in a synergistic fashion, but this has not been determined.

It is hoped that this positive report will serve as further motivation to conduct formal trials to definitively establish whether LDN is a safe and effective human cancer therapy.

Acknowledgements

The author wishes to thank Dr. Humaira Khan and Dr. Martin Black for their assistance, and also the patient Mr. Michel Charest (michel.charest@hotmail.com) for consenting to publish his case.

Author Disclosure Statement

The author works at a clinic where naltrexone is dispensed for a fee. The clinic is owned by a family member of the author.

References

1. Yancey JR, Lumbad AJ. Opioid antagonists for the treatment of alcohol dependence. *American Family Physician*. 2011; **84**: 990-992.
2. Zagon IS, McLaughlin PJ. Opioid Growth Factor (OGF) inhibits anchorage-independent growth in human cancer cells. *International Journal of Oncology*. 2004; **24**: 1443-1448.
3. Zagon IS, Verderame MF, McLaughlin PJ. The expression and function of the OGF-OGFr axis - a tonically active negative regulator of growth - in COS cells. *Neuropeptides*. 2003; **37**: 290-297.
4. McLaughlin PJ, Levin RJ, Zagon IS. Opioid Growth Factor (OGF) inhibits the progression of human squamous cell carcinoma of the head and neck transplanted into nude mice. *Cancer Letters*. 2003; **199**: 209-217.
5. Cheng F, McLaughlin PJ, Verderame FM, Zagon IS. The OGF-OGFr axis utilizes the p21 pathway to restrict progression of human pancreatic cancer. *Molecular Cancer*. 2008; **7**: 5.
6. McLaughlin PJ, Zagon IS, Park SS, Conway A, Donahue RN, Goldenberg D. Growth inhibition of thyroid follicular cell-derived cancers by the Opioid Growth Factor (OGF) - Opioid Growth Factor Receptor (OGFr) axis. *BMC Cancer*. 2009; **9**: 369.
7. Smith JP, Conter RL, Bingaman SI, Harvey HA, Mauger DT, Ahmad M, Demers LM, Stanley WB, McLaughlin PJ, Zagon IS. Treatment of advanced pancreatic cancer with opioid growth factor: phase I. *Anticancer Drugs*. 2004; **15**: 203-209.
8. Zagon IS, Jaglowski JR, Verderame MF, Smith JP, Leure-Dupree AE, McLaughlin PJ. Combination chemotherapy with gemcitabine and biotherapy with Opioid Growth Factor (OGF) enhances the growth inhibition of pancreatic adenocarcinoma. *Cancer Chemotherapy and Pharmacology*. 2005; **56**: 510-520.
9. Smith JP, Bingaman SI, Mauger DT, Harvey HH, Demers LM, Zagon IS. Opioid growth factor improves clinical benefit and survival in patients with advanced pancreatic cancer. *Open Access Journal of Clinical Trials*. 2010; **2010**: 37-48.
10. Mathews PM, Froelich CJ, Sibbitt WL Jr, Bankhurst AD. Enhancement of natural cytotoxicity by beta-endorphin. *Journal of*

Immunology. 1983; **130**: 1658-1662.

11. Berkson BM, Rubin DM, Berkson AJ. The long-term survival of a patient with pancreatic cancer with metastases to the liver after treatment with the intravenous alpha-lipoic acid/low-dose naltrexone protocol. *Integrative Cancer Therapies*. 2006; **5**: 83-89.

12. Berkson BM, Rubin DM, Berkson AJ. Reversal of signs and symptoms of a B-cell lymphoma in a patient using only low-dose naltrexone. *Integrative Cancer Therapies*. 2007; **6**: 293-296.

13. Berkson BM, Rubin DM, Berkson AJ. Revisiting the ALA/N (alpha-lipoic acid/low-dose naltrexone) protocol for people with metastatic and nonmetastatic pancreatic cancer: A report of 3 new cases. *Integrative Cancer Therapies*. 2009; **8**: 416-422.

14. Bonnet S, Archer SL, Turner JA, Haromy A, Beaulieu C, Thompson R, Lee CT, Lopaschuk GD, Puttagunta L, Bonnet S, Harry G, Hashimoto K, Porter CJ, Andrade MA, Thebaud B, Michelakis ED. A mitochondrial K⁺ channel axis is suppressed in cancer and its normalization promotes apoptosis and inhibits cancer growth. *Cancer Cell*. 2007; **11**: 37-51.

15. Flavin DF. Non-Hodgkin's Lymphoma Reversal with Dichloroacetate. *Journal of Oncology*. 2010; **2010**.

16. Michelakis ED, Sutendra G, Dromparis P, Webster L, Haromy A, Niven E, Maguire C, Gammer TL, Mackey JR, Fulton J, Abdulkarim B, McMurtry MS, Petruk KC. Metabolic modulation of glioblastoma with dichloroacetate. *Science Translational Medicine*. 2010; **2**: 31-34.

17. Brewer GJ, Robert DD, Grover DK, LeClaire V, Tseng M, Max Wicha, Pienta K, Redman BG, Jahan T, VK, Carpentier GL, Merajver SD. Treatment of metastatic cancer with tetrathiomolybdate, an anticopper, antiangiogenic agent: Phase I study. *Clinical Cancer Research*. 2000; **6**: 1-10.

18. Redman BG, Esper P, Pan Q, Dunn RL, Hussain HK, Chenevert T, Brewer GJ, Merajver SD. Phase II trial of tetrathiomolybdate in patients with advanced kidney cancer. *Clinical Cancer Research*. 2003; **9**: 1666-1672.

19. Brewer GJ, Merajver SD. Cancer therapy with tetrathiomolybdate: Antiangiogenesis by lowering body copper; A review. *Integrative Cancer Therapies*. 2002; **1**: 327-337.

20. Pass HI, Brewer GJ, Dick R, Carbone M, Merajver S.

A phase II trial of tetrathiomolybdate after surgery for malignant mesothelioma: Final results. *Annals of Thoracic Surgery*. 2008; **86**: 383-389.

21. Pols HA, Birkenhäger JC, Foekens JA, Van Leeuwen JP. Vitamin D: A modulator of cell proliferation and differentiation. *The Journal of Steroid Biochemistry and Molecular Biology*. 1990; **37**: 873-876.

22. Studzinski GP, McLane JA, Uskokovic MR. Signaling pathways for vitamin D-induced differentiation: implications for therapy of proliferative and neoplastic diseases. *Critical Reviews in*

Eukaryotic Gene Expression. 1993; **3**: 279-312.

23. Zhao X, Feldman D. Regulation of vitamin D receptor abundance and responsiveness during differentiation of HT-29 human colon cancer cells. *Endocrinology*. 1993; **132**: 1808-1814.

24. Srivastava MD, DeLuca HF, Ambrus JL. Differentiation of neoplastic cells toward normal induced by vitamin D3 derivatives. *Research Communications in Chemical Pathology and Pharmacology*. 1994; **83**: 115-123.

25. Moskaluk CA. Adenoid cystic carcinoma: Clinical and molecular features. *Head and Neck Pathology*. 2013; **7**: 17-22.